Rom J Rheumatol 2024, 33(3):118-122 ISSN (print) 1843–0791, ISSN (online) 2069–6086

Revista Română de Reumatologie
Romanian Journal of Rheumatology

CASE REPORT

Ankylosing Spondylitis and Spontaneous Chronic Urticaria – Two Faces of Autoimmunity

DOINITA OPREA[1,2)], MIHAELA MINEA[1,3)], MADALINA GABRIELA ILIESCU[1,2,3)], LILIANA ELENA STANCIU[1,2)], CLAUDIA ILEANA MIHAILOV[2,4)]

[1)]*Balnear and Rehabilitation Sanatorium Techirghiol, Romania*
[2)]*Faculty of Medicine, "Ovidius" University of Constanta, Romania*
[1)]*Doctoral School of Medicine, "Ovidius" University of Constanta, Romania*
[2)]*Railway Clinical Hospital, Constanta, Romania*

Abstract

Background. Chronic spontaneous urticaria (CSU) is a common pathology with a prevalence of 1-2% in the population. Chronic underlying infection and mental and emotional stress can sometimes precede the onset of CSU and, once established, can exacerbate the symptoms. The most common comorbidities are autoimmune thyroiditis, vitiligo, atopic pathology, chronic inflammation and psychiatric disorders, such as depression and anxiety. Patients with CSU have an increased risk of comorbid autoimmune diseases, with 0.07-0.1% being associated with ankylosing spondylitis (AS).

Methods. We report a clinical case of a 52-year-old patient diagnosed in 2007 with ankylosing spondylitis (AS) axial form, who has been on treatment with Adalimumab, a tumor necrosis factor-alpha (TNF-alpha) inhibitor since 2016, following the regimen outlined in the product's Summary of Product Characteristics (SmPC). In April 2024, the patient was diagnosed with chronic spontaneous urticaria.

Results. Given the severe and progressive course of CSU, we discontinued the TNF-alpha inhibitor treatment. The patient underwent a 3-month course of antihistamines and corticosteroids, administered both orally and topically, which proved to be clinically ineffective. Ultimately, the dermatologist initiated treatment with a humanized IgG1-type anti-IgE antibody.

Conclusion. The prompt recognition of CSU in the context of autoimmunity and its association with AS has a significant impact on therapeutic management, involving the concurrent or selective use of a tumor necrosis factor (TNF) inhibitor and a humanized IgG-type anti-IgE antibody.

Keywords: chronic spontaneous urticaria, ankylosing spondylitis, autoimmunity, efficacy and safety.

Introduction

Chronic spontaneous urticaria is a debilitating skin disease characterized by intensely itchy wheals, angioedema, or both. Symptoms recur spontaneously, on a near-daily basis, over >6 weeks; many patients experience flare-ups over several years and, consequently, reduced quality of life. Both children and adults can develop CSU, although it is more common in adults and in women than in men, with a peak occurrence in the third to fifth decades of life. It imposes a significant burden on patients, families and healthcare systems [1]. Many cytokines and chemokines involved in these inflammatory networks and their corresponding intracellular signaling cascades have been identified. The biomarkers currently known and used for diagnosis and assessment of CSU are: immunoglobulins (Total Ig E, IgG), Anti-TPO (anti-thyroperoxidase antibodies), TSH (thyroid stimulating hormone), Ig E to FcεRI (ASST positivity), D-dimer, Interleukins and other cytokines (IL-6, IL-17, IL-23, IL-31, TNFα), CD203, CD63, CCL17, CRP S100 family (S100A8, S100A9, and S100A12) (17-22) [2]. There are two types of CSU, type 1 type 1 based on an auto-allergic mechanism and associated with a high level of Ig E, and type II determined by an hypersensitivity reaction with low level of IgE [3,4].

These insights informed the development of therapies such as omalizumab, dupilumab, and Bruton's tyrosine kinase (BTK) inhibitors, marking a renewed focus on pathogenesis in CSU clinical research. Despite progress, current therapies provide symptomatic control but do not appear to redress the inflammatory balance in the skin permanently [5].

Chronic spontaneous urticaria (CSU) can be accompanied by a multitude of comorbidities, including autoimmune, atopic, or psychiatric disorders. A systematic review of the literature regarding autoimmune comorbidities showed that the most common were thyroid gland disorders and vitiligo, while the most frequently circulating

This is an open-access article distributed under the terms of a Creative Commons Attribution-NonCommercial-ShareAlike 4.0 International Public License, which permits unrestricted use, adaptation, distribution and reproduction in any medium, non-commercially, provided the new creations are licensed under identical terms as the original work and the original work is properly cited.

autoantibodies were anti-thyroid and anti-nuclear antibodies (ANA) [6]. Another meta-analysis demonstrated that urticarial eruptions frequently occur in systemic lupus erythematosus (SLE). It is believed that the presence of rheumatoid arthritis in patients with chronic urticaria reflects an overall inflammatory state that destabilizes mast cells and thereby causes urticaria, while in SLE, vitiligo, and autoimmune thyroiditis, the pathogenesis is primarily driven by the presence of specific autoantibodies [7]. The pathogenesis of CSU is still debated, but it is clear that the activation of mast cells and basophils leads to the release of pro-inflammatory mediators that support the development of urticaria [8].

In 2012 World Allergy Organization (WAO) published a position paper on the diagnosis and treatment of urticaria with a global vision. Since then, greater experience with the use of biologics, mainly omalizumab, in patients with severe disease has been acquired [7]. Omalizumab is the first available humanized monoclonal anti-Ig E with a pediatric indication, too (age ≥6 years) [8].

Case Report

We present the case of a 52-year-old patient diagnosed in 2007 with axial spondylarthritis, who tested positive for HLA-B27 and received treatment with Adalimumab, an TNF-alpha inhibitor until April 2024. The disease progressed favorably, with remission of clinical and biological manifestations. In April 2024, he presented for a follow-up with a disseminated erythematous-edematous urticarial rash on the cephalic region (frontal, occipital, malar), which was pruritic and also affected the mucous membranes, resembling angioedema. The skin lesions had persisted for approximately 24 hours. Under treatment with antihistamines (Bilastine, Levocetirizine dihydrochloride, Rupatadine, Chlorpheniramine) and corticosteroids (Prednisone, Methylprednisolone, Hydrocortisone hemisuccinate), the urticarial lesions expanded to the trunk and limbs, with a chronic recurrent evolution.

In August 2024, the patient was admitted to the dermatology clinic, where he was investigated for signs of systemic disease or chronic infection through a clinical interview. Urine analysis and culture, throat swab for streptococci, and an ice cube test for cold-induced urticaria were performed. Additional tests included a urea breath test for Helicobacter pylori diagnosis, stool culture, chest and sinus X-rays, and skin prick tests for common aero- or food allergens. Blood samples were taken for a complete blood count, electrolytes, thyroid-stimulating hormone, antinuclear antibodies, C-reactive protein, hepatitis B and C screening, as well as immunoglobulins A, E, G, and M, along with kidney and liver function tests.

The paraclinical investigations revealed mild leukocytosis (L=14.37 thousand/microL), with neutrophilia and lymphocytosis, persistently elevated IgE levels (281.8 UI/mL vs. 100 UI/mL), and a moderate inflammatory syndrome (CRP=1.9 mg/dL vs. 0.5). Weakly positive antinuclear antibodies (1:160) with granular cytoplasmic fluorescence were noted, while the extensive ANA blot was negative, and anti-DNA, G6-PDH, and serum complement antibody levels were normal.

Skin biopsy showed mild edema and sparse lymphocytes localized perivascularly in the superficial dermis, with occasional neutrophils and eosinophils present in the interstitium. This minimal inflammation with edema supports the diagnosis of urticaria.

Based on clinical and paraclinical data, the final diagnosis was chronic spontaneous urticaria (CSU), and treatment with Omalizumab 300 mg was initiated once every four weeks. Omalizumab is a recombinant monoclonal antibody that inhibits the high-affinity Fc receptor of IgE, proving effective in patients with refractory chronic urticaria. Managing chronic urticaria that does not respond to high-dose antihistamines poses a therapeutic challenge, and in such cases, alternative systemic treatment options should be considered. The national dermatological protocol was followed, and biological therapy was initiated.

The patient was followed up in our outpatient clinic monthly after the initiation of Omalizumab therapy, in order to identify any adverse reactions or if the treatment was not successful.

Favorable response to treatment was observed within the first month after initiation of Omalizumab treatment. However, to achieve long-term relief of urticaria symptoms, continuous treatment with this recombinant monoclonal antibody will be necessary, as its discontinuation could lead to a return of symptoms within a few weeks.

(a)

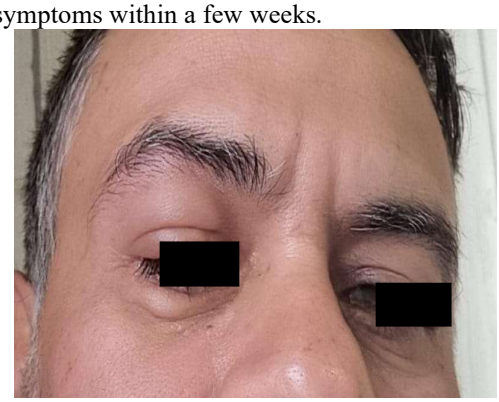

(b)

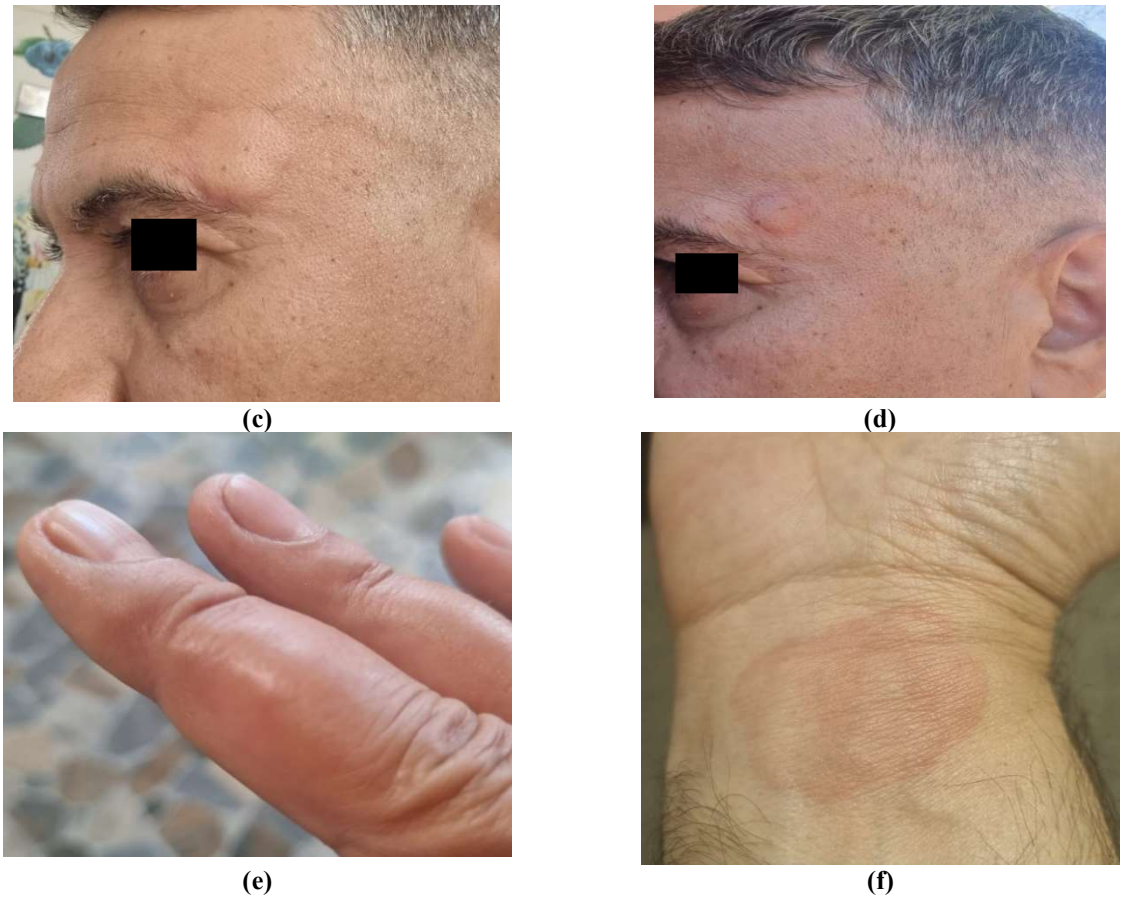

Figure 1. *Clinical aspects (May-July 2024) skin lesions on the head, fingers and forearm.*

Given the gradual reinstatement of inflammatory pain symptoms at the vertebral level in the context of spondylarthritis, approximately six months after stopping Adalimumab, it will be necessary to reintroduce a remission-inducing treatment, most likely a biological therapy.

Discussions

A typical patient with CSU is an adult with high disease activity and concomitant autoimmune disease(s), predominantly autoimmune thyroiditis and/or vitiligo, and a family history of autoimmune disorder [2].

The goal of therapy in patients with CSU is to achieve a level of symptom control and improvement in quality of life that is acceptable to the patient, while minimizing therapy-related side effects. The current therapeutic algorithm for CSU, endorsed by international guidelines, entails treatment escalation of second-generation H1-antihistamines up to 4-fold if symptom control is not adequate. If complete response is not achieved, Omalizumab is additionally administered [8].

Omalizumab (OMA) is the only biological medication currently approved for the treatment of patients with AH-refractory moderate to severe CSU, a monoclonal antibody (m Ab) directed to the Cϵ3 domain of human Ig E heavy chain, the same site that binds to Fc receptors on mast cells and basophils. Efficacy and safety of OMA in CSU have been demonstrated in double-blind placebo-controlled studies, and confirmed through meta-analysis. Dosing recommended for Omalizumab is 150 mg or 300 mg q4 weeks [7, 9].

Many studies have shown that patients who partially respond to the standard dose of 300 mg every 4 weeks can benefit from dose increases [10].

Omalizumab is generally well tolerated, and the most common adverse effects include injection site reactions, viral infections, upper respiratory infections, sinusitis, and headaches [8]. Patient monitoring is often recommended after the first three doses of the drug because anaphylaxis—although rare—is more likely to occur within this time frame. In the last 2 years, the FDA has also approved home self-administration of Omalizumab [11].

The optimal duration of therapy has not been determined, and patients may relapse when Omalizumab is tapered or discontinued. Also, Omalizumab has not been shown to have a long-term disease-modifying effect in CSU [8].

Since the crucial role of mast cells in the pathogenesis of UC, their ability to release TNF-alpha as well as the high levels of TNF-alpha found in CSU lesions, the administration of anti-TNF-alpha (Etanercept, Infliximab, Adalimumab) have been tested in adult patients, with success [12]. Successively, the anti-TNF-α has been reported to be effective in 60% of 20 CSU patients, including some Omalizumab non-responders, with CSU [13].

The theoretical basis for the use of TNF-alpha targeting therapy is supported by a study that has

shown that TNF-alpha is upregulated in patients with chronic urticaria compared with healthy controls. In addition, it has been shown that TNF-alpha is expressed throughout the epidermis in both lesional and no lesional skin of patients with chronic urticaria but not in healthy controls [14]. Interestingly the cytokine profile in the skin of patients with chronic urticaria mimics that found in patients with psoriasis, psoriatic arthritis, and rheumatoid arthritis with increased expression of TNF-alpha and IL-10 and decreased expression of IL-2 and interferon gamma.

In conclusion, this study suggests that TNF-alpha inhibitors could be considered in patients with severe chronic urticaria where other treatment options are contra indicated have been unsuccessful or have been associated with unacceptable adverse reactions.

The term spondylarthritis refers to a group of immune-mediated diseases characterized by inflammation of the axial skeleton, peripheral joints, and entheses. Ankylosing spondylitis (AS) is the most common and characteristic of these entities and even though it was first described over two centuries ago, the understanding of the underlying disease mechanism remains incomplete. Also, more genes and new molecules have demonstrated a role in the pathogenesis of AS.

The HLA-B27 allele is known to have a strong association with the disease [15]; however, other genes play a part in its development. The discovery of several inflammatory pathways led to the era of the biologic therapies, which meant a revolution in the treatment and prognosis of AS. Tumor necrosis factor inhibitors (TNFi) were the first ones to be approved, but in the last few years the interleukin-17 (IL-17)/IL-23 axis has gained relevance, culminating in the license of new biological disease modifying antirheumatic drugs (bDMARDs) blocking IL-17 [16].

Given the onset of chronic spontaneous urticaria (CSU) in a patient with another chronic autoimmune condition (spondylarthritis) already undergoing treatment with Adalimumab, a TNF-alpha inhibitor included in the therapeutic guidelines for CSU, it was deemed appropriate to initiate treatment with Omalizumab.

Considering the pathogenesis, prevalence, and chronic nature of the disease, the risk of encountering additional conditions complicates treatment for physicians.

We also considered a possible adverse reaction to Adalimumab, as urticaria is a less common cutaneous adverse reaction according to the product's summary of product characteristics (SmPC). However, this was subsequently ruled out due to the chronicity of the skin condition despite the discontinuation of Adalimumab.

Searching the literature we a found a case of a female treated with Adalimumab for Psoriasis (Ps) and Psoriasis Arthritis (PsA) who developed CSU. The anti TNF-alpha therapy wasn't stopped and omalizumab was associated for 24 months, when dermatological symptoms being relived, the anti-Ig E agent [17].

Recently, few reports of concomitant use of biological therapies in such challenging cases have been reported [18]. Limited data exist on the combined use of Omalizumab and other biologics. A study published in 2016 which included 9 patients with CSU treated with Adalimumab 40 mg/week after a loading dose of 80 mg showed complete remission in 3 cases, partial improvement for 4 of them and no effect on 2 subjects [19].

Another case of a female with Ps treated with Methotrexate who associated CSU, was reported in 2022. Incomplete controlled by antihistaminic, Omalizumab was added, and a month later Secukinumab was introduced for Ps. After 4 weeks the CSU symptoms were remitted, and after another 5 months the Omalizumab was stopped. Two years later the patient is in remission for CSU, following Secukinumab for Ps [20].

Current data from the literature shows that the duration of combined biologic therapy use ranged between 3 and 12 months, the biological agents used being inhibitors of TNF- alpha or Secukinumab. A recent article published in 2023, concluded that omalizumab used for CSU associated with other biological therapy applied for skin diseases seems not to have major side effects. It was a study which followed the safety of medication and included 31 patients, 17 from them following Omalizumab and Secukinumab in the same time [21].

However, we didn't find any cases of spondyloarthrits associated with CSU.

Considering all these factors, the most plausible treatment would be the combination of Secukinumab and Omalizumab in the event that the spondylarthritis clinically and paraclinically exacerbates. Alternatively, Secukinumab could be initiated after discontinuing Omalizumab following the remission of CSU symptoms.

Conclusions

Biologic therapies are molecules that target specific proteins implicated in immune mediated disease. It is promising that successful results have been reported in a small number of case reports of the concomitant use of biological agents. Prospective studies are needed to better understand the efficacy and safety of these combinations. The high cost of treatment and the lack of long-term safety data require careful selection and close follow-up of patients.

Conflicts of Interest: The authors declare no conflicts of interest.

Informed Consent Statement: Informed consent was obtained from all subjects involved in the study.

References

[1] Licari A, Manti S, Leonardi S et al. Biologic drugs in chronic spontaneous urticaria. Vol. 92, Acta Biomedica. Mattioli 1885; 2021.

[2] Kolkhir P, Muñoz M, Asero R et al. Autoimmune chronic spontaneous urticaria. Vol. 149, Journal of Allergy and Clinical Immunology. Elsevier Inc.; 2022. p. 1819–31.
[3] Tan IJ, Podwojniak A, Parikh A et al. Precision Dermatology: A Review of Molecular Biomarkers and Personalized Therapies. Vol. 46, Current Issues in Molecular Biology. Multidisciplinary Digital Publishing Institute (MDPI); 2024. p. 2975–90.
[4] Altrichter S, Fok JS, Jiao Q et al. Total ige as a marker for chronic spontaneous urticaria. Vol. 13, Allergy, Asthma and Immunology Research. Korean Academy of Asthma, Allergy and Clinical Immunology; 2021. p. 206–18.
[5] Kaplan A, Lebwohl M, Giménez-Arnau AM et al. Chronic spontaneous urticaria: Focus on pathophysiology to unlock treatment advances. Vol. 78, Allergy: European Journal of Allergy and Clinical Immunology. John Wiley and Sons Inc; 2023. p. 389–401.
[6] Gevaert E, Yousefi S, Bachert C et al. Reply. Vol. 141, Journal of Allergy and Clinical Immunology. Mosby Inc.; 2018. p. 1164–5.
[7] Sánchez-Borges M, Ansotegui IJ, Baiardini I et al. The challenges of chronic urticaria part 2: Pharmacological treatment, chronic inducible urticaria, urticaria in special situations. Vol. 14, World Allergy Organization Journal. Elsevier Inc.; 2021.
[8] Licari A, Manti S, Leonardi S et al. Biologic drugs in chronic spontaneous urticaria. Vol. 92, Acta Biomedica. Mattioli 1885; 2021.
[9] Maurer M, Rosén K, Hsieh HJ et al. Omalizumab for the Treatment of Chronic Idiopathic or Spontaneous Urticaria. New England Journal of Medicine. 2013 Mar 7;368(10):924–35.
[10] Metz M, Vadasz Z, Kocatürk E et al. Omalizumab Updosing in Chronic Spontaneous Urticaria: an Overview of Real-World Evidence. Vol. 59, Clinical Reviews in Allergy and Immunology. Springer; 2020. p. 38–45.
[11] Fiorino I, Loconte F, Rucco AS et al. Long-term treatment of refractory severe chronic urticaria by omalizumab: Analysis of two cases. Vol. 31, Postepy Dermatologii i Alergologii. Termedia Publishing House Ltd.; 2014. p. 332–4.
[12] Foster SB, Paul ME, Kozinetz CA et al. Prevalence of asthma in children and young adults with HIV infection. Vol. 119, Journal of Allergy and Clinical Immunology. 2007. p. 750–2.
[13] Sand FL, Thomsen SF. TNF-Alpha Inhibitors for Chronic Urticaria: Experience in 20 Patients. J Allergy (Cairo). 2013 Sep 18;2013:1–4.
[14] A B Abbreviations used AU: Acute urticaria CRU: Chronic recurrent urticaria DPU: Delayed pressure urticaria ICAM: Intercellular adhesion molecule.
[15] Chen B, Li J, He C et al. Role of HLA-B27 in the pathogenesis of ankylosing spondylitis (Review). Mol Med Rep. 2017 Apr 1;15(4):1943–51.
[16] Garcia-Montoya L, Gul H, Emery P. Recent advances in ankylosing spondylitis: Understanding the disease and management. Vol. 7, F1000Research. F1000 Research Ltd; 2018.
[17] Diluvio L, Vollono L, Zangrilli A et al. Omalizumab and adalimumab: A winning couple. Immunotherapy. 2020 Dec 1;12(18):1287–92.
[18] Fougerousse AC, Becherel PA, Pallure V et al. Combining omalizumab with another biotherapy. Acta Derm Venereol. 2019 Apr 1;99(4):448–9.
[19] Bangsgaard N, Skov L, Zachariae C. Treatment of refractory chronic spontaneous urticaria with adalimumab. Vol. 97, Acta Dermato-Venereologica. Medical Journals/Acta D-V; 2017. p. 524–5.
[20] Abdelmaksoud A, Temiz SA, Daye M et al. Response of chronic refractory psoriasis vulgaris with urticaria to combined secukinumab and omalizumab: A case report and review of the literature. Vol. 22, Journal of Cosmetic Dermatology. John Wiley and Sons Inc; 2023. p. 1416–8.
[21] Koç Yıldırım S, Erbağcı E, Hapa A. Omalizumab treatment in combination with any other biologics: Is it really a safe duo? Australas J Dermatol. 2023 May;64(2):229-233. doi: 10.1111/ajd.14019. Epub 2023 Mar 3. PMID: 36866918.

Corresponding author
Doinita Oprea, Faculty of Medicine, "Ovidius" University of Constanta, Romania, doi_opr@yahoo.com

Received: 07.11.2024

Accepted: 28.11.2024